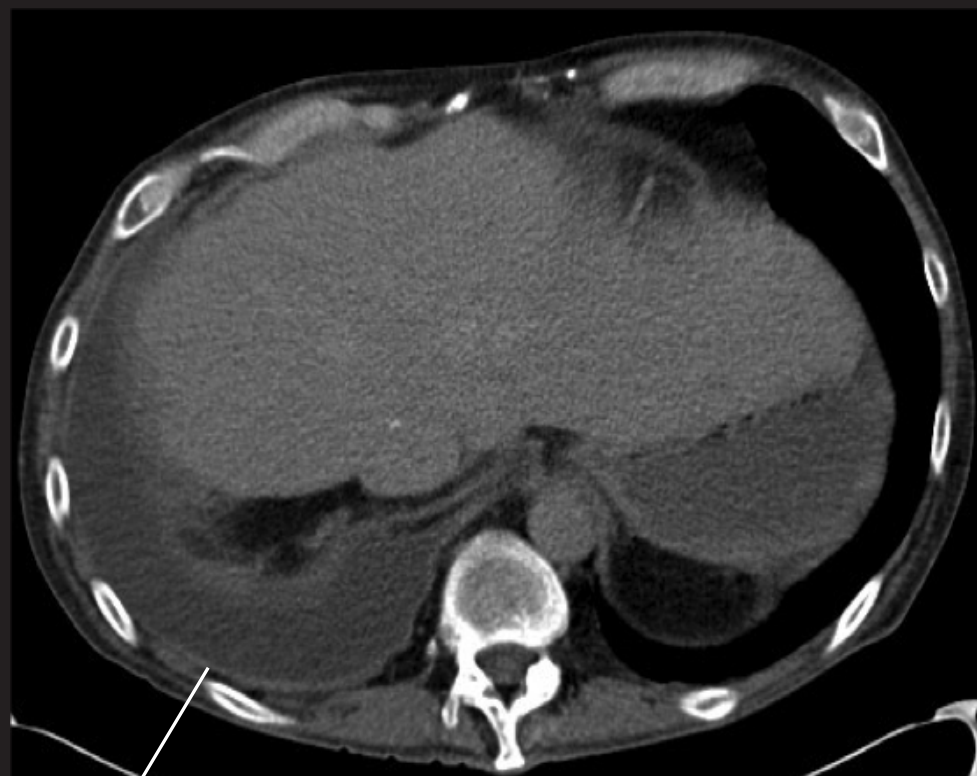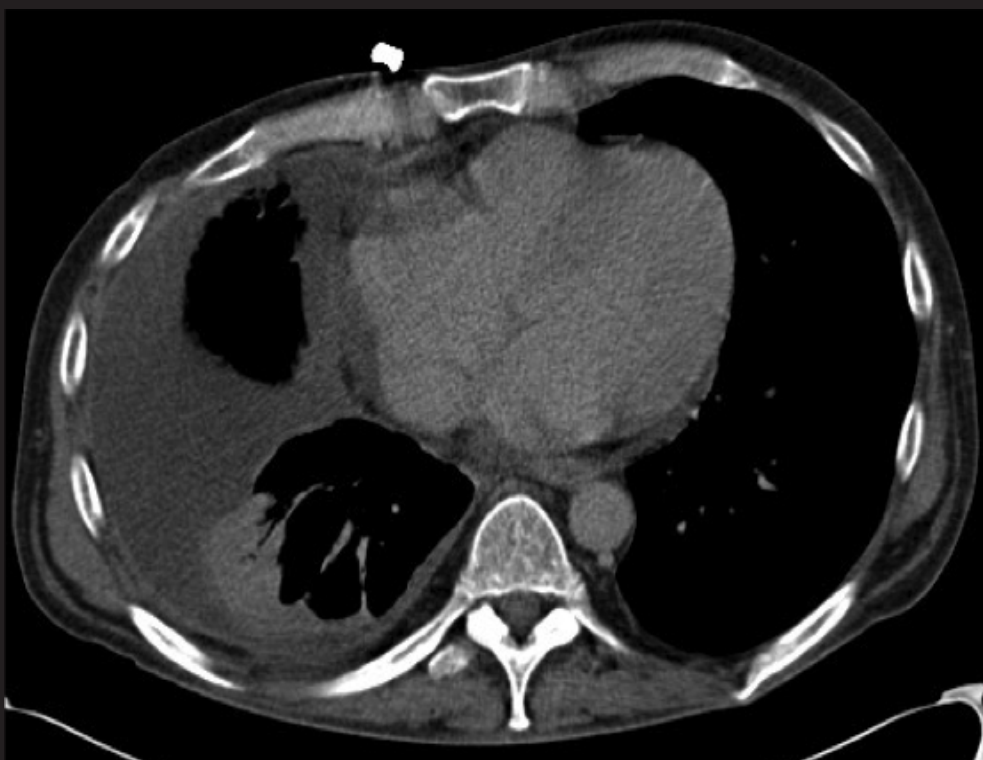
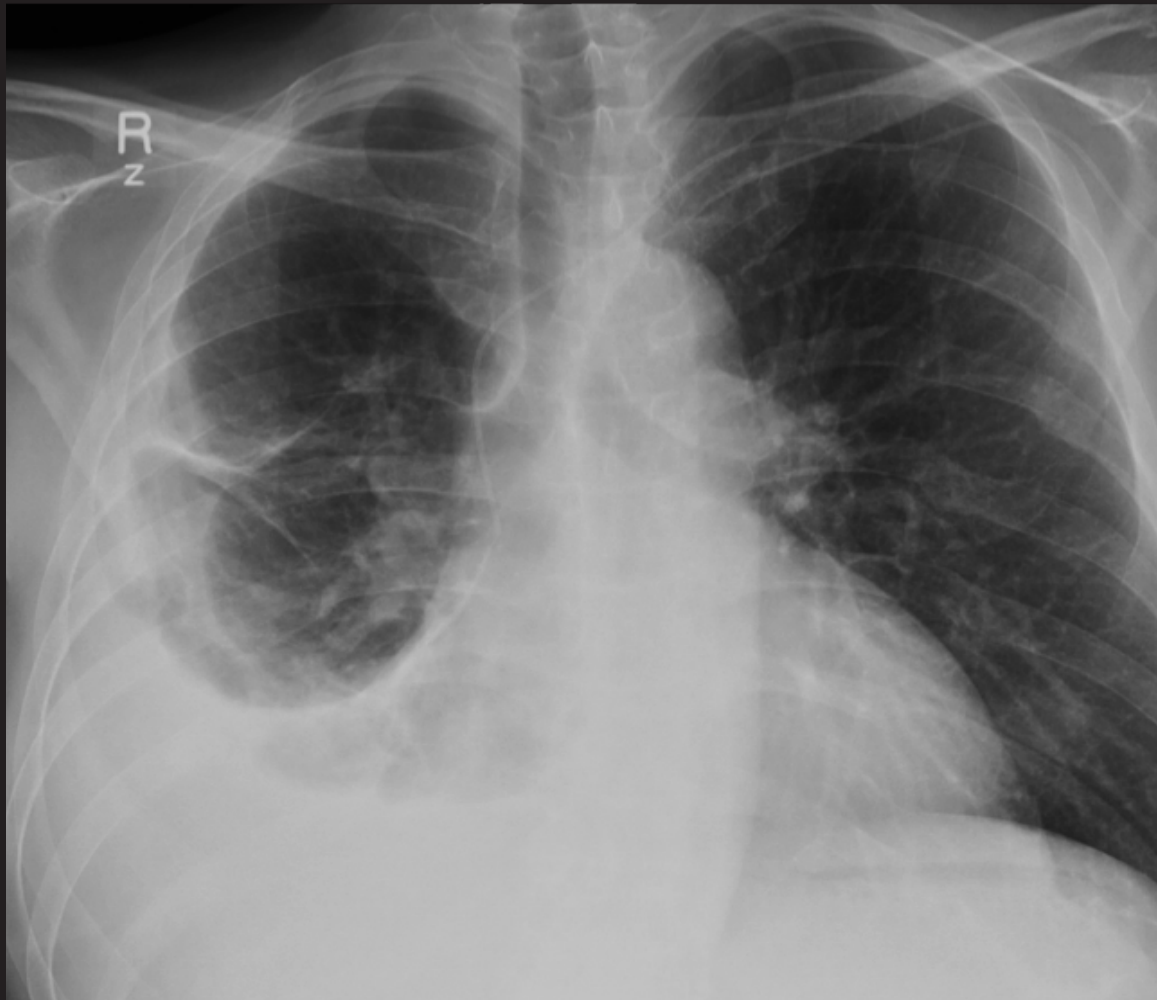


Empyema thoracis

Chest X-ray demonstrating a loculated right pleural effusion; this is confirmed on CT, on which pleural enhancement is also visible, typical of an empyema.



Pleural enhancement